



ENTAMOEBEA HISTOLYTICA AND OTHER RHIZOPHODIA

38.1 INTRODUCTION

Amoebae can be pathogenic called *Entamoeba histolytica* and non pathogenic called *Entamoeba coli* (large intestines), *Entamoeba gingivalis* (oral cavity). These parasites are motile with pseudopodia. The pseudopodia are cytoplasmic processes which are thrown out.



OBJECTIVES

After reading this lesson you will be able to:

- describe morphology, its life cycle, pathogenicity of *Entamoeba histolytica*, other amoebae and free living amoeba
- differentiate between amoebic and Bacillary dysentery
- differentiate between *Entamoeba histolytica* and *Entamoeba coli*
- demonstrate Laboratory diagnosis of *Entamoeba*

38.2 ENTAMOEBEA HISTOLYTICA

It belongs to the class Rhizopoda and family Entamoebidae. It is the causative agent of amoebiasis. Amoebiasis can be intestinal and extra intestinal like amoebic hepatitis, amoebic liver abscess.

38.3 MORPHOLOGY

The *Entamoeba* is seen in three stages

- (a) **Trophozoite:** The trophozoite is 18-40 μm in size. The trophozoite is actively motile. The cytoplasm is demarcated into endoplasm and ectoplasm. Ingested food particles and red blood cells are seen in the cytoplasm. No bacteria are seen in the cytoplasm. The nucleus is 6-15 μm and has a central rounded karyosome. Nuclear membrane has chromatin granules and spoke like radial arrangement of chromatin fibrils.



Notes

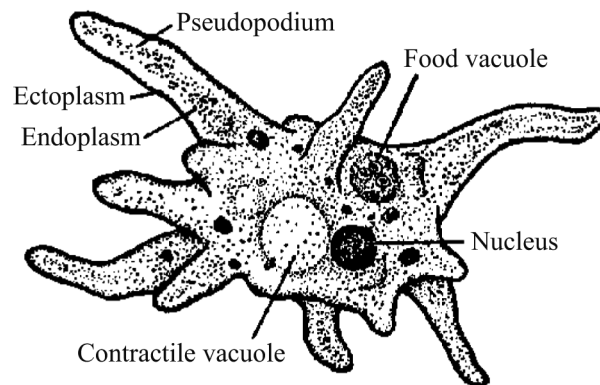


Fig. 38.1

- (b) **Precyst:** Smaller in size. 10-20 μm in diameter. It is round to oval in shape with blunt pseudopodium. The nuclei is similar to the trophozoite.
- (c) **Cyst:** These are round 10-15 μm in diameter. It is surrounded by a refractile membrane called as the cyst wall. The cyst wall makes it resistant to gastric juices. The nuclei are similar to the trophozoite. Mature cyst has four nuclei. The nuclei initially divides into two and then to four by binary fission. The uninucleate and binucleate stage also has a glycogen mass. Cysts are seen only in the lumen of the colon and in the stools.

38.4 LIFE CYCLE OF ENTAMOEBIA HISTOLYTICA

The life cycle is spent in only one host i.e. man. The mature quadrinucleate cysts are the infective forms. The cysts are ingested in food and water and reach the caecum or the lower part of ileum where the excystation of the cyst occurs. The mature cyst liberates a single amoeba with four nuclei (Tetranucleate amoeba). The nuclei further divide to produce the eight metacystic trophozoites. These trophozoites lodge in the submucosa of large intestine. In the large intestines they grow and multiply by binary fission.

38.5 STRAIN DIFFERENTIATION

Strain differentiation is done phenotypically on the basis of isoenzyme patterns called zymodemes. The isoenzymes used for strain differentiation are glucose

MODULE

Microbiology



Notes

Entamoeba Histolytica and Other Rhizophodia

phosphoisomerase (GPI), phosphoglucomutase (PGM). Here are twenty two zymodemes identified

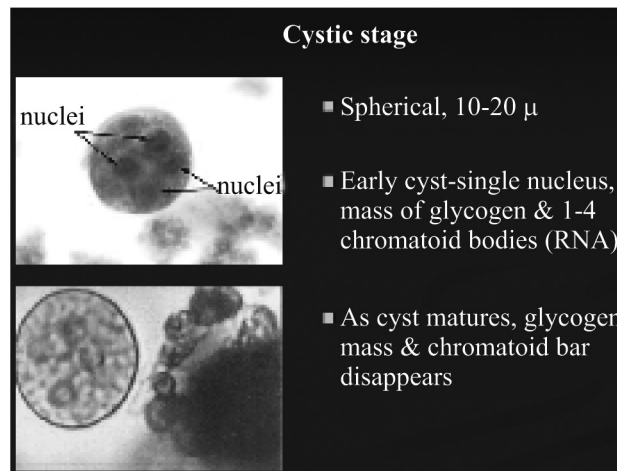


Fig. 38.2

Table 38.1 Differentiating features between amoebic and bacillary dysentery

	Differentiating feature	Amoebic dysentery	Bacillary dysentery
1	Causative agent	Entamoeba histolytica	Shigella species
2	Number of stools	6-8	10-14
3	Volume of stools	Large	Small
4	Odour	Foul smelling	No odour (as fecal matter is absent)
5	Blood	Altered brown coloured blood present in stools	Bright red blood is present
6	Tenesmus (Pain and discomfort on passage of stools)	Absent	Present
7	pH of stools	Acidic	Basic
8	Microscopy	Trophozoites of E histolytica seen	No trophozoites seen
9	Culture	Commensals grown	Shigella grown
10	Pus cells	Few	Many
11	Eosinophils	Present	Absent
12	Charcot- Layden crystals	Present	Absent

38.6 PATHOGENECITY

After an incubation period ranging from 4-5 days to 3-4 weeks the disease starts presenting as loose diarrhea which may have blood and stool mixed in it. E histolytica secretes a proteolytic enzyme which causes destruction and necrosis of intestinal mucosal tissue leading to formation of flask shaped ulcers. A large number of trophozoites and cysts mixed with blood and mucus are excreted in the faeces presenting as dysentery which is referred to as amoebic dysentery. Some trophozoites gain entry into the portal vein and reach the liver. In the liver it can cause. The pus in the liver abscess is reddish brown in colour and is like anchovy sauce.

- (a) Amoebic hepatitis
- (b) Amoebic liver abscess.

The trophozoites transform to precyst and cysts and cysts are excreted in faeces. The mature cyst is the infective form of E histolytica.

38.7 LABORATORY DIAGNOSIS

Specimen

In case of amoebic dysentery : loose stools mixed with blood and mucus

In case of amoebic liver abscess: Anchovy sauce like pus aspirated with ultrasound guided fine needle aspiration from the liver abscess.

Direct microscopy : A small amount of the stool is mixed with a drop of normal saline and another drop is mixed with 2% iodine solution. These slides are examined under a light microscope. Diagnosis is established by demonstrating trophozoite or cyst forms in the stools.or pus sample The trophozoites are recognized by the presence of red blood cells in the cytoplasm. In the case of saline preparation motile trophozoite forms may be seen, In cold weather the stage needs to be kept warm at 37 °C

Serology: Blood specimen is used for serological tests for the diagnosis of amoebiasis.. Tests available are Immuno Haem Agglutination, and ELISA.

ELISA tests detect antibodies to E histolytica antigen



INTEXT QUESTIONS 38.1

1. The causative agent of Amboeiasis is
2. The stages in the life cycle of Entameba are, &



Notes

MODULE

Microbiology



Notes

Entamoeba Histolytica and Other Rhizophodia

3. The pH of stools in Ameobic dysentery is
4. The extra-intestinal ameobiasis are &
5. The causative agent for Bacillary dysentery is species

38.8 MISCELLANEOUS AMOEBAE

1. **Entamoeba coli** is prevalent worldwide and are non pathogenic. Its life cycle is similar to Entamoeba histolytica. It also has three stages i.e.

Trophozoites

Precystic

Cystic

Table No 38.2. Difference between E histolytica and E coli

	Differentiating features	E histolytica	E coli
	Trophozoite		
1.	Size	18-40 μm	20-40 μm
2.	Motility	Actively motile	Sluggishly motile
3.	Cytoplasm	Clearly demarcated into endoplasm and ectoplasm	Endoplasm and ectoplasm are not clearly demarcated
4.	Cytoplasmic inclusions	Red blood cells (RBCs), leucocyte and tissue debris. No bacteria is seen.	Bacteria & tissue debris is seen but no Red blood cells (RBCs), or leucocytes are inclusions seen.
5.	Nucleus	Not visible in unstained preparation	Visible in unstained preparation
6.	Karyosome	Central	Eccentric
7.	Nuclear membrane	Delicate and is lined by fine chromatin	Thick and is lined by coarse chromatin
	Cyst		
8.	Size	6-15 μm	15-20 μm
9.	Nucleus	1-4,	1-8
10.	Karyosome	Central karyosome	Eccentric karyosome
11.	Chromatid bars	Rounded	Filamentous

2. **Entamoeba gingivalis**

- (a) E gingivalis is a parasite of the human mouth and may be present as commensal especially in cases of pyorrhea alveolaris (infections of the gums).



- (b) They are 10-20 μm in size
- (c) It is actively motile
- (d) Its cytoplasm is divided into a clear ectoplasm and a granular endoplasm.
- (e) The cytoplasmic inclusions consist of bacteria, leucocytes and other materials but it never consists of red blood cells.
- (f) The nucleus is spherical with central karyosome.
- (g) The nuclear membrane is lined with closely packed chromatin granules

3. Entamoeba dispar:

- (a) It is a non-invasive and non pathogenic amoeba.
- (b) It is identical to E histolytica. The cysts are also similar.
- (c) However the red cells are not seen in the cytoplasm .

4. Entamoeba hartmanii

- (a) It is morphologically similar to E histolytica but is smaller in size.
- (b) The trophozoites never contain red blood cells in the cytoplasm.
- (c) It is non pathogenic

5. Endolimax nana

- (a) They are small amoeba which are found in large intestines of man and animals.
- (b) The trophozoites are small 6-15 μm in size.
- (c) The cytoplasm is demarcated into ectoplasm and endoplasm.
- (d) The cytoplasmic inclusions consist of bacteria, leucocytes and other materials but it never consists of red blood cells.
- (e) The nucleus is spherical with large irregular karyosome lying eccentrically.
- (f) Several achromatic strands extend from karyosome to nuclear membrane
- (g) The cysts are oval in shape and measure 8-10 μm in diameter.
- (h) The mature cysts are quadrinucleate.
- (i) Chromatid bodies and glycogen are present in the cysts.

6. Iodamoeba butschlii

- (a) They are present in large intestine of humans, monkeys and pigs.
- (b) Its trophozoites are 6-20 μm in diameter.
- (c) The ectoplasm is not well demarcated.

MODULE

Microbiology



Notes

Entamoeba Histolytica and Other Rhizophodia

- (d) The nucleus is large 2-3.5 μm . The karyosome is central, large and circular.
- (e) The cyst is ovoid or pyriform in shape. The chromatid bars are absent.



INTEXT QUESTION 38.2

State True or False(T/F)

1. E coli are actively motile
2. E. Histolytica the nucleus is visible in unstained preparation
3. The Cytoplasm is clearly demarcated into Endoplasm and Ectoplasm in E. Histolytica
4. Karyosomes are Eccentric in E. Coli

38.9 FREE LIVING AMOEBIA

Pathogenic free living amoeba are found in water bodies and soil. They can often become the cause of Primary amoebic meningoencephalitis (PAM) and Chronic amoebic keratitiss.

1. **Naegleria fowleri**:- It was named so after Fowler and Carter who described it first from Australia in 1965. They can cause meningo encephalitis.

Trophozoites have amoeboid form and flagellate form

(a) Amoeboid

- (i) They are 10-20 μm in size and appear elongated. They have rounded pseudopodia called lobopodia.
- (ii) The nucleus has a large central karyosome and no peripheral nuclear chromatin.
- (iii) They are actively motile.
- (iv) The soil amoeba convert to flagellate form.

(b) Flagellate

- (i) They are pear shaped with two flagella at its anterior end.
- (ii) It moves rapidly forward and spins slowly.
- (iii) The flagellate forms do not multiply.

(c) Cyst

- (i) They are 7-10 μm in size.
- (ii) They are surrounded by a thin cyst wall
- (iii) They lack glycogen or chromotoidal bars
- (iv) They are not seen in the cerebro spinal fluid.

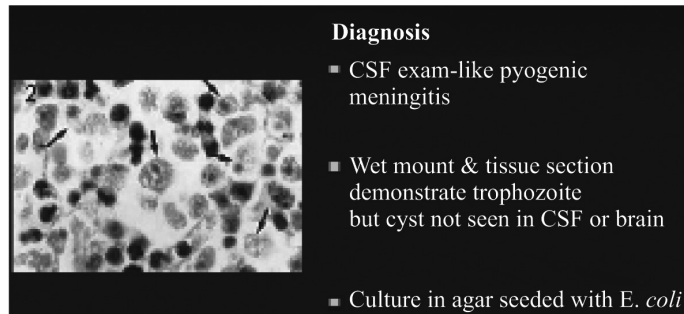


Fig. 38.3

2. **Pathogenicity:** Human beings acquire the infection during swimming or diving into water bodies containing the free living amoeba. The amoeba invades the nasal mucosa and pass through the cribriform plate and reach the olfactory nerve. From here they invade the meninges and cause meningitis and encephalitis. The disease if not treated in time invariably results in fatality.
3. **Laboratory Diagnosis:** The laboratory diagnosis is established by examining the cerebro spinal fluid from a suspected case of meningoencephalitis. The CSF is cloudy and may be purulent with prominent neutrophilic leucocytosis. Wet preparation examination will demonstrate the trophozoites.



WHAT HAVE YOU LEARNT

- Intestinal amoeba are pathogenic called *Entamoeba histolytica* and non pathogenic called *Entamoeba coli* and *Entamoeba gingivalis*
- *Entamoeba histolytica* belongs to the class Rhizopoda and is the causative agent of amoebiasis.
- Amoebiasis can be intestinal and extra intestinal like amoebic hepatitis, amoebic liver disease
- *Entamoeba* is seen in three stages namely Trophozoite, Precyst and Cyst stage and the life cycle is spent in only one host i.e. man.
- *Entamoeba histolytica* secretes a proteolytic enzyme which causes destruction and necrosis of intestinal mucosal tissue leading to formation of flask shaped ulcers.
- Diagnosis is established by demonstrating trophozoite or cyst forms in the stools.
- *Entamoeba coli* are non pathogenic and the life cycle is similar to *Entamoeba histolytica*
- *Entamoeba gingivalis* is a parasite of human mouth and may be present as commensals especially in cases of pyorrhea alveolaris



Notes

MODULE

Microbiology



Notes

Entamoeba Histolytica and Other Rhizophodia

- Entamoeba dispar is non-invasive and non-pathogenic amoeba
- Endolimax nana are small amoeba which are found in large intestines of man and animals
- Pathogenic free living amoeba are found in water bodies and soil and are cause primary amoebic meningoencephalitis and chronic amoebic keratitis.
- Human being acquire the infection during swimming or driving into water bodies containing free living amoeba
- The laboratory diagnosis of free living amoeba is established by examining the cerebro spinal fluid from suspected case of meningoencephalitis.



TERMINAL QUESTIONS

1. Discuss the life cycle and pathogenicity of Entamoeba histolytica.
2. Discuss the laboratory diagnosis of amoebic dysentery
3. Enumerate the difference between amoebic and bacillary dysentery.
4. Name the free living amoeba and discuss their pathogenicity and laboratory diagnosis.



ANSWERS TO INTEXT QUESTIONS

38.1

1. Entamoeba Histolytica
2. Trophozoite, Precystic stage, Cyst
3. Acidic
4. Amoebic hepatitis, Amoebic Liver abscess

38.2

1. False
2. False
3. True
4. True