

MODULE

Hematology and Blood
Bank Technique



Notes

10

MATURATION AND DEVELOPMENT OF LEUCOCYTES

10.1 INTRODUCTION

The leucocytes develop from the multipotent hematopoietic stem cell which then gives rise to a stem cell committed to formation of leucocytes. Both these cells cannot be identified morphologically by routine methods. The various types of leucocytes are granulocytes (neutrophils, eosinophils and basophils), monocytes and lymphocytes. The three cell types develop separately and accordingly these processes will be discussed separately.



OBJECTIVES

After reading this lesson, you will be able to:

- explain the various stages in the development of leucocytes.
- describe the different types of leucocytes seen normally in PBF.

10.2 MYELOPOIESIS

This is the process of formation of myeloid cells. It is restricted to the bone marrow after birth. The committed progenitor cell for granulocytes and monocytes is the **GM-CFU** which proliferates and differentiates to form myeloblast and monoblast.

The **myeloblast** is the earliest morphologically identifiable cell. It is 10-18µm in size. The cytoplasm is scant and basophilic, usually agranular and may contain a few azurophilic cytoplasmic granules in the blast transiting to the next stage

Maturation and Development of Leucocytes

of promyelocyte. It has a large round to oval nucleus with a smooth nuclear membrane. The chromatin is fine, lacy and is evenly distributed throughout the nucleus. Two-five nucleoli can be identified in the nucleus.

The next stage of maturation is the **Promyelocyte**. It is larger than a myeloblast, 12-20 µm with more abundant cytoplasm which has abundant primary azurophilic granules. The nucleus is round to oval, has slightly more condensed chromatin and nucleoli are not prominent.

The next stage is the **Myelocyte** which is identified as being smaller than a promyelocyte, 12-18 µm. The cytoplasm is eosinophilic and an eccentric round to oval nucleus with coarse chromatin and no visible nucleoli can be seen. **Specific granules** appear in the cytoplasm at this stage and therefore, a myelocyte can be identified as a neutrophilic, eosinophilic or basophilic myelocyte based on the staining properties of the secondary granules. These granules are smaller than the azurophilic granules.



INTEXT QUESTIONS 10.1

1. Types of leucocytes are, &
2. Types of granulocytes are, &
3. Process of formation of myeloid cells are
4. Earliest morphologically identified cell is

Metamyelocyte is easily identified by its smaller size, dense and clumped chromatin and an indented, horse shoe shaped nucleus with no nucleoli. The cytoplasm is filled with primary, secondary and tertiary granules but the secondary granules predominate. The presence of granules and their staining properties determine whether it is neutrophilic, eosinophilic or basophilic metamyelocyte.

Neutrophilic metamyelocytes give rise to **band form** in which the nucleus becomes sausage shaped with further condensation of the chromatin.

Finally the **polymorphonuclear neutrophil** is formed which has coarsely clumped nuclear chromatin and 3-5 lobes in the nucleus. The lobes are connected by filamentous strands of chromatin.

Cell division is limited to myeloblast, promyelocyte and myelocyte. With the later stages undergoing differentiation but no further cell division. Hence myeloblasts, promyelocytes and myelocytes comprise the **proliferative or mitotic compartment**, whereas cells from metamyelocyte stage onwards comprise the **maturation storage compartment** of the bone marrow.

MODULE

Hematology and Blood
Bank Technique



Notes

MODULE

Hematology and Blood
Bank Technique



Notes

Maturation and Development of Leucocytes

The **half life of neutrophils** in circulation is 6-8 hrs. On completion of the life span, cells may undergo apoptosis or phagocytosis by macrophages, or undergo cell death through mechanisms dependent on reactive oxygen metabolite.

Eosinophils and basophils follow the same pattern of proliferation, differentiation, maturation and storage in the bone marrow. The **eosinophils** are recognized by their coarse, bright orange reddish granules and a bi or trilobed nucleus. The half life of eosinophils is approx 18 hrs.

Basophils are similar in size to a lymphocyte, have abundant coarse, purplish black granules overlying and obscuring the nucleus. The granules contain histamine, heparin, proteases.

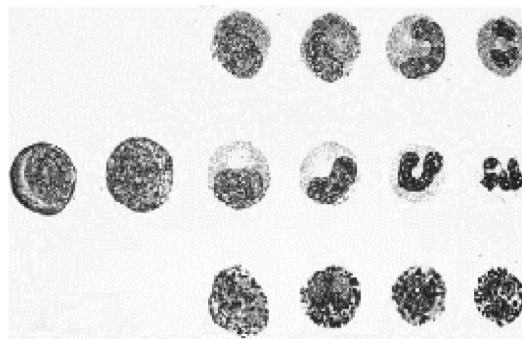


Fig. 10.1: centre row From left to right:myeloblast, promyelocyte, myelocyte, metamyelocyte, band form and mature neutrophil. The top row depicts development of eosinophils and the bottom row development of basophils

Formation of monocytes

The committed progenitor cell GM-CFU also differentiates to form monoblast under the influence of GM-CSF and M-CSF. **Monoblast** is morphologically similar to myeloblast. Monoblast gives rise to **promonocyte** which has basophilic cytoplasm, an indented nucleus, fine chromatin, and may contain a nucleolus. They mature into **Monocytes** which are 15-18 μm in size with a large centrally placed oval or indented nucleus, delicate chromatin and no nucleoli. The cytoplasm is abundant, pale blue in color and has a ground glass appearance due to numerous clear or lilac vacuoles. Monocytes have a short half life in blood of 4.5 to 10 hrs only and migrate from the blood to reside in various tissues as **tissue macrophages**.

Formation of lymphocytes : Lymphopoiesis

The mature lymphocytes are a heterogenous population of cells that differ from each other in terms of origin, lifespan and preferred sites of location within the lymphoid organ. The earliest identifiable precursor is a **Lymphoblast**. It is 14-18 μm in size, with scant basophilic cytoplasm and high nuclear: cytoplasmic

Maturation and Development of Leucocytes

(N/C) ratio. The nucleus shows coarse clumped chromatin with 1-2 prominent nucleoli. The lymphoblasts mature to **prolymphocytes** which are smaller cells, 10-12 µm in size with scant cytoplasm, more condensed chromatin and 0-1 nucleoli. The mature lymphocyte can be a **small lymphocyte** approximately 8-10µm in size with deep purplish blue round or slightly indented nucleus and dense chromatin. Nucleoli are not present. There is a very small rim of basophilic cytoplasm. In the **large granular lymphocyte** the cytoplasm is more abundant and contains several reddish granules. Both forms are seen in peripheral blood.

Around 60 - 80% of lymphocytes in the peripheral blood are T cells while B cells constitute about 10-15% of peripheral blood lymphocyte population.

For formation of B cells, the lymphoid progenitor gives rise to a **Precursor B cell** which forms the **immature B cell** and finally the **mature B cell**. B lymphocytes are not stored in the BM except for a brief period and are released into circulation to populate the secondary lymphoid organs. The B cells occupy the lymphoid follicles.

Each of these stages can be identified by the expression of certain **cell surface antigens** which can be detected by immunophenotyping. Some of these antigens are described.

Table 10.1

Cell	Antigen
Progenitor B cell	TdT, CD34, CD19, Ig gene rearrangement
Pre B cell	cIg, CD 10, CD 19, CD20
Immature B cell	sIg, CD 19, CD20. TdT, CD 34 and CD 10 are not expressed
Mature B cell	coexpression of surface IgD (high) and IgM (low), CD 20, CD 22.

This expression of antigens is used in the classification of leukemias and lymphomas.

The **T cells** populate the perifollicular cortical areas in the lymph node. They are derived from **progenitors** which migrate to the **thymus** where they settle in the **corticomedullary junction**. **The stages in the development of T cells are similar to B cells**. The antigens expressed in each of the stages are described now

The earliest progenitor cells committed to the development of T cells express TdT and CD 34.

The immature cortical thymocytes express CD7, TdT, cCD3 and like B lymphocytes undergo TCR gene rearrangement. On further maturation

MODULE

Hematology and Blood
Bank Technique



Notes

MODULE

Hematology and Blood Bank Technique

Maturation and Development of Leucocytes

coexpression of CD 4 and CD8 occurs and later with further maturation the mature T cells express either CD4 or CD 8 antigen.



Notes

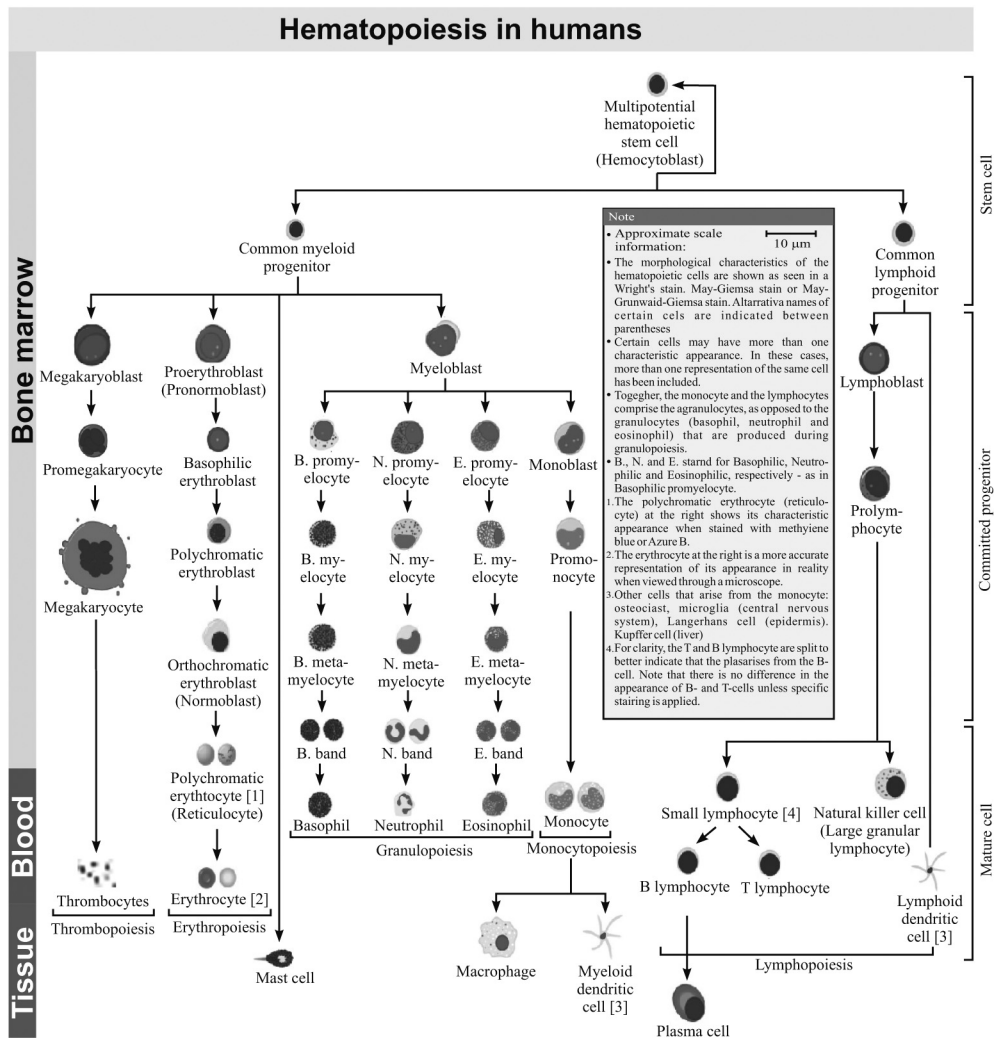
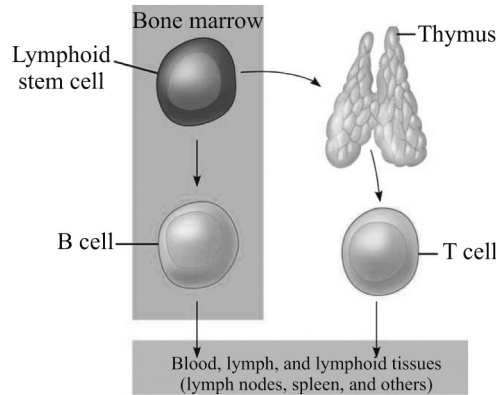


Fig. 10.2: Formation of monocytes, lymphocytes, neutrophil, eosinophil, basophil, red cells and platelets



INTEXT QUESTIONS 10.2

1. Band form arises from
2. Two compartments of bone marrow involved in myelopoiesis are & compartment.
3. Monoblast mature into
4. Tissue macrophages are
5. Precursor for lymphocytes are
6. The stages of cell development are by and are detected by

10.3 FUNCTIONS OF WHITE CELLS

Neutrophils are phagocytic cells which migrate to the site of microbial infection, and kill the microorganisms.

Monocytes and tissue macrophages also have microbicidal activity although, less effective than that of neutrophils. They are also involved in **phagocytosis and degradation of necrotic material**.

Eosinophils are involved in **defence against parasites and in allergic reactions**.

Basophils along with mast cells are store houses of inflammatory mediators that are released during **IgE mediated hypersensitivity reactions** and are responsible for the associated inflammatory response and tissue injury.

Lymphocytes are non phagocytic cells. Both B and T lymphocytes with their subsets are actively involved in **humoral and cell mediated immunity** through their interaction with monocyte –macrophage system.

Cells seen in peripheral smear

Polymorphonuclear neutrophil: This cell has an eosinophilic cytoplasm, coarsely clumped nuclear chromatin and a lobulated nucleus, in which the lobes are connected by filamentous strands of chromatin. Two types of granules are present in the mature neutrophils- **primary granules** or azurophilic granules which contain myeloperoxidase, lysozyme, acid phosphatase and acid hydrolase mainly and **secondary granules** or **specific granules** which contain lysozymes, alkaline phosphatase and lactoferrin mainly.

Eosinophil: These cells are about 8 μ in diameter and are recognized by their coarse, bright orange reddish granules and a bilobed nucleus. The lobes are larger than those of the neutrophils.

MODULE

Hematology and Blood
Bank Technique



Notes

MODULE

Hematology and Blood
Bank Technique



Notes

Maturation and Development of Leucocytes

Basophils are 10-15 μm in size, have abundant coarse, purplish black granules which fill the cytoplasm and obscure the nucleus.

Lymphocytes: Most lymphocytes in blood are small, about 10 μm in size though larger forms are also present. The nucleus stains deep purplish blue, is round or slightly indented and has dense chromatin. Nucleoli are not visible. There is a narrow rim of basophilic cytoplasm, which is more abundant in the large lymphocyte. Granules are present in the larger forms.

Monocytes are 15-18 μm in size with a large centrally placed oval or indented nucleus with delicate chromatin and no nucleoli. The cytoplasm is abundant pale blue gray in colour and has a ground glass appearance due to numerous clear or lilac vacuoles.

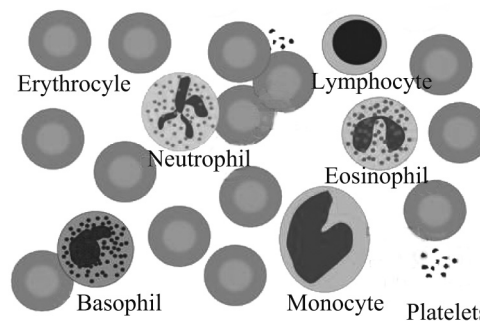


Fig. 10.3



INTEXT QUESTIONS 10.3

Match the following

- | | |
|----------------|--|
| 1. Neutrophils | (a) Hypersensitivity reactions |
| 2. Eosinophils | (b) Humoral and cell mediated immunity |
| 3. Basophils | (c) Phagocytic cells |
| 4. Lymphocytes | (d) Involved in allergic reactions |

Normal white cell count

The normal value of total leucocyte count in different age groups is given below.

Table 10.2

Group	TLC $\times 10^9/L$
Adults	4-11
Infants at birth	9-30
6 months-2 years	6-17.5
Children 4-7 years	5-15
Children 8-12 years	4.5-13.5

Maturation and Development of Leucocytes

The counts are higher in infancy and childhood than in adults. The counts drop over the first seven days of life to about $14 \times 10^9/L$. there is an increase in TLC in pregnancy and following parturition. Counts also tend to be higher in the afternoon.

Absolute leucocyte count

The absolute count for a particular type of blood cell is the total white blood cell count multiplied by the differential percentage for that cell type.

Normal value of absolute count of leucocytes

Table 10.3

Cell	Absolute count $\times 10^9/L$
Neutrophil	1.8-7.7
Lymphocyte	1.0-4.8
Eosinophil	0.04-0.5
Monocyte	0.2-1.0
Basophil	0.01-0.1

Neutropenia

This implies a decrease in the number of neutrophils with an absolute count $< 1500 \text{ cells}/\mu\text{l}$. based on the count neutropenia can be mild ($1000-1500 \text{ cells}/\mu\text{l}$), moderate ($500-1000 \text{ cells}/\mu\text{l}$) and severe ($< 500 \text{ cells}/\mu\text{l}$).

Causes of neutropenia

- Bacterial infections such as typhoid, tuberculosis, gram- negative sepsis
- Viral infections such as hepatitis B, cytomegalovirus, Epstein-Barr virus, human immunodeficiency virus, hepatitis C virus
- Drugs
- Immune-mediated causes
- Transfusion reactions
- Neonatal alloimmune neutropenia
- Chronic autoimmune neutropenia
- Chronic idiopathic neutropenia
- Pure white cell aplasia
- Autoimmune disorders: systemic lupus erythematosus, rheumatoid arthritis, Wegener's granulomatosis

MODULE

Hematology and Blood
Bank Technique



Notes

MODULE

Hematology and Blood
Bank Technique



Notes

Maturation and Development of Leucocytes

Nutritional causes: megaloblastic anaemia, copper deficiency, zinc excess

Bone marrow disorders: aplastic anaemia, replacement by lymphoma, leukaemia, myelofibrosis, multiple myeloma

Congenital or chronic neutropenias

Cyclic neutropenia

Inborn errors of metabolism

10.4 TOTAL LEUCOCYTE COUNT AND DIFFERENTIAL LEUCOCYTE COUNT

TLC

White blood cells or leucocytes can be counted manually in the laboratory using a Neubauer chamber.

Principle

Blood is diluted with Turk's fluid which lyses the red cells and colors the leucocytes which can then be counted.

Sample

Venous blood collected in EDTA.

Equipment required

Hemocytometer which has

- WBC pipette which has a white bead in the bulb and the stem has markings of 0.5, 1 and 11.
- Improved Neubauer chamber



Fig. 10.4: WBC pipette: Note the white bead in the bulb and the markings



Reagents required

- Turk's fluid which contains
Glacial acetic acid 2ml
1% gentian violet 5 drops
Add water to make 100ml

Method

- Mix the blood sample well gently.
- Fill blood in the WBC pipette upto 0.5 mark. Wipe the excess blood.
- Fill the pipette upto 11 mark with Turk's fluid.
- Rotate the pipette in the palm of the hand to mix blood and diluting fluid.
- Discard the first 2 drops and charge the Neubauer chamber after placing a cover slip over the area with the markings. Place the tip of the pipette close to the cover slip while charging the chamber. There should be no air bubbles in the area after charging.
- Wait for 2-3 minutes.
- Count the white cells under the microscope in the 4 corner squares each of which has 16 squares.
- $$\text{TLC (X109/L)} = \frac{N \times 20}{4 \times 0.1} \quad \text{i.e. } N \times 50$$

N : number of cells counted in 4 squares
20 is the dilution
0.1 is the depth of the chamber

Notes

Alternative method of diluting blood for TLC

Take 3.8ml of Turk's fluid in a 75x10 mm glass tube and add 0.2 ml of blood to it. Charge the Neubauer chamber using a Pasteur pipette.

Table 10.4 Normal value of TLC in different age groups

Group	TLC × 10 ⁹ /L
Adults	4-11
Infants at birth	9-30
6months-2 years	6-17.5
Children 4-7 years	5-15
Children 8-12 years	4.5-13.5

MODULE

Hematology and Blood
Bank Technique



Notes

Maturation and Development of Leucocytes

Precautions

1. The Neubauer chamber must be clean and free from dust.
2. There should be no air bubbles in the Neubauer chamber after charging.

Sources of error

1. Dust particles or clumped red cell debris may be counted as leucocytes.
2. Clumping of leucocytes may also cause error.

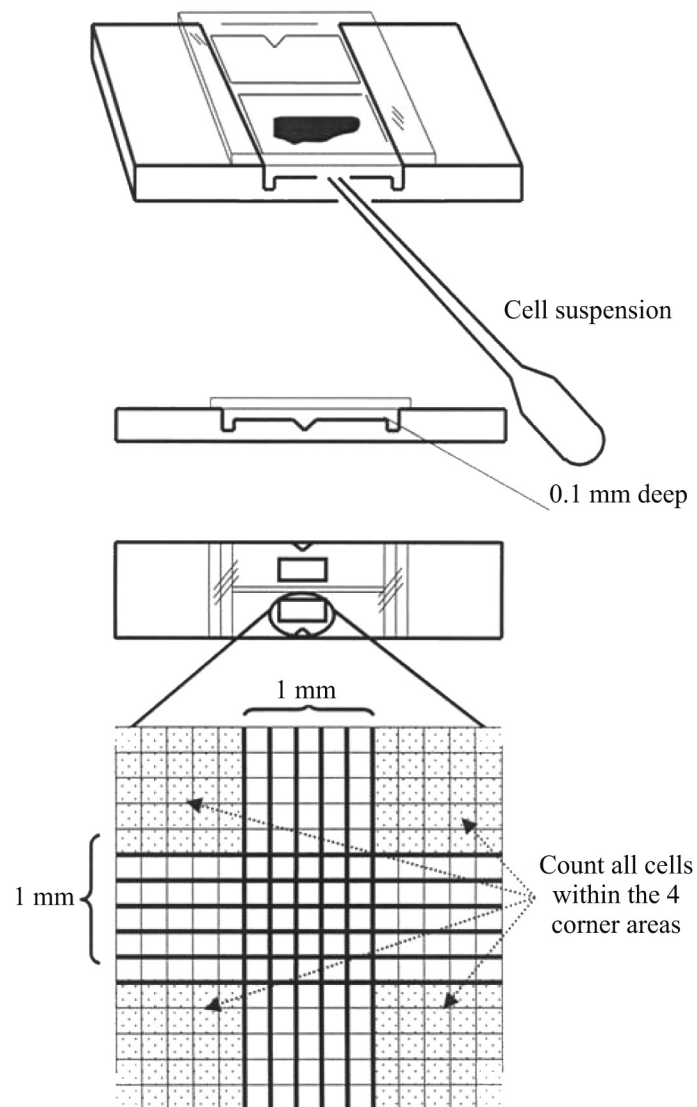


Fig. 10.5: Improved Neubauer chamber: Charging it and WBC counting is done in the 4 squares marked

Differential leucocyte count (DLC)

This refers to enumeration of different types of leucocytes on a stained peripheral smear. One hundred cells are counted and the number of each cell type is expressed as a percentage.

Apply a thin layer of oil over the stained smear and identify the area where DLC is to be done by first examining the smear under low power.

Count the cells using a40x objective in the identified area.

Move the slide in a zig zag manner till at least 100 cells are counted while avoiding the lateral edges of the smear.

Note the different types of leucocytes in the zone of morphology shown in the figure just next to the tail and express as a percentage.



Notes

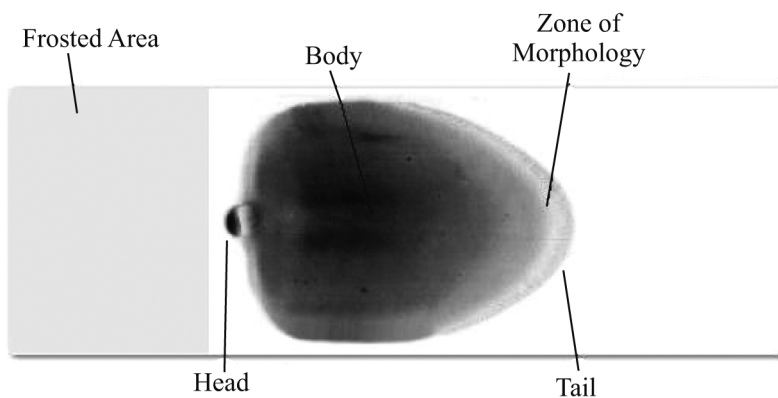


Fig. 10.6: Differential Leucocyte Count

Cells seen in peripheral smear

Polymorphonuclear neutrophil: This cell has an eosinophilic cytoplasm, coarsely clumped nuclear chromatin and a lobulated nucleus, in which the lobes are connected by filamentous strands of chromatin. Two types of granules are present in the mature neutrophils- primary granules or azurophilic granules which contain myeloperoxidase, lysozyme, acid phosphatase and acid hydrolase mainly and secondary granules or specific granules which contain lysozymes, alkaline phosphatase and lactoferrin mainly.

Eosinophil: These cells are about 8μ in diameter and are recognized by their coarse, bright orange reddish granules and a bilobed nucleus. The lobes are larger than those of the neutrophils.

Basophils are $10-15\mu$ in size, have abundant coarse, purplish black granules which fill the cytoplasm and obscure the nucleus.

Lymphocytes: Most lymphocytes in blood are small, about 10μ in size though larger forms are also present. The nucleus stains deep purplish blue, is round or

MODULE

Hematology and Blood
Bank Technique



Notes

Maturation and Development of Leucocytes

slightly indented and has dense chromatin. Nucleoli are not visible. There is a narrow rim of basophilic cytoplasm, which is more abundant in the large lymphocyte. Granules are present in the larger forms.

Monocytes are 15-18 μm in size with a large centrally placed oval or indented nucleus with delicate chromatin and no nucleoli. The cytoplasm is abundant pale blue gray in colour and has a ground glass appearance due to numerous clear or lilac vacuoles.

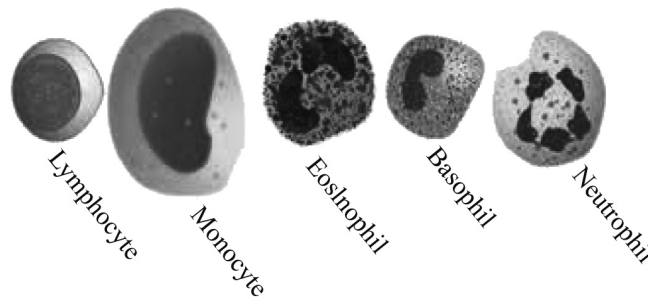


Fig. 10.7: Peripheral smear

Normal value of DLC

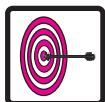Table 10.5

Cell	%
Neutrophils	40-75
Lymphocytes	20-40
Eosinophils	2-6
Monocytes	2-10
Basophils	0-1



INTEXT QUESTIONS 10.4

1. Normal TLC in adults (a) 1.8 – 7.7/L
2. TLC in infants at birth (b) 4 – 11/L
3. Normal neutrophil count (c) 0.04 – 0.5/L
4. Normal eosinophil count (d) 9 – 30/L



WHAT HAVE YOU LEARNT

- Leucocytes develop from multipotent hematopoietic stem cell
- Leucocytes are Granulocytes, Monocytes and Lymphocytes
- Granulocytes are Neutrophils, Eosinophils and Basophils

Maturation and Development of Leucocytes

- Process of formation of myeloid cells is Myelopoiesis
- Neutrophils are phagocytic cells which migrate to the site of microbial infection
- Monocytes & Macrophages have microbicidal activity
- Eosinophils are involved in defense against parasites and in allergic reactions
- Basophils are released during IgE mediated hypersensitivity reactions
- Lymphocytes are non phagocytic cells



TERMINAL QUESTIONS

1. Explain Myelopoiesis
2. What are the functions of white cell



ANSWERS TO INTEXT QUESTIONS

10.1

1. Granulocytes, monocytes & lymphocytes
2. Neutrophils, eosinophils & basophils
3. Myelopoiesis
4. myeloblast

10.2

1. Neutrophilic metamyelocytes
2. Proliferative & maturation storage
3. Monocytes
4. Monocytes
5. Lymphoblast
6. Cell surface antigens, immunophenotyping

10.3

1. c 2. d 3. a 4. b

10.4

1. b 2. d 3. a 4. c

MODULE

Hematology and Blood
Bank Technique



Notes